

## FIRST CASE OF DICEPHALY IN ODONTOCETI

TOSHIRO KAMIYA\*, NOBUYUKI MIYAZAKI\*\* AND  
SATOSHI SHIRAGA\*\*\*

\* Anatomical Laboratory, College of Medical Technology, University of Tsukuba, Ibaraki

\*\* Department of Zoology, National Science Museum, Tokyo

\*\*\* Department of Marine Sciences, University of the Ryukyus, Naha, Okinawa

It is well known that many types of teratological specimens have been found among mammals including man. However, there are few reports of such cases in Cetacea. Kawamura (1969) describes Siamese twins in the sei whale (*Balaenoptera borealis*). These were male bodies measuring 114 and 137 cm in length respectively. They were considered a typical morphological example of complete ventral fusion from the throat to a point just anterior to the navel. There was one umbilical cord only, the fusion between both taking place along their posterior margins. Zemsky and Budylenko (1970) reported an almost identical case of twin female foetuses in the humpback whale (*Megaptera novaeangliae*) with body-lengths 124 and 120 cm respectively.

A double monster of the striped dolphin (*Stenella coeruleoalba*) has been observed by Kawamura and Kashita (1971). That was a malformed embryo with two body-lengths 16.8 and 17.2 cm along a rostro-caudal axis. Kamiya and Miyazaki (1974) also described the early developmental stage in a *Stenella* embryo 9 mm long cranio-caudally, affected with several malformations.

In this note, we wish to report the first known case of *duplicitas anterior* in Odontoceti. The specimen was collected off the Pacific coast of Japan's Kii Peninsula (33°36'N, 135°56'E) on December 14, 1979. It consists of a teratological female foetus taken from the left uterus of a *Stenella coeruleoalba*. The mother's body-length was 221 cm. Its age, as determined from the count of both dentinal and cemental growth, was estimated to be about 14.5 years. There was one corpus luteum and three corpora albicantia in the left ovary and no corpora in the right one, which indicates a young mother. Pictures of the monster are herewith presented and the following comments can be made.

1) The specimen shows a rostral duplication that affects the front portion of the head. Fusion begins dorsally at the blow-hole level and ends immediately behind the throat. The vertebral column is strongly curved cranio-caudally in a C-shaped line. The cranio-caudal body-length is 85.7 cm on the left side, 85.8 cm on the right side. The total body-weight is 7.0 Kg. 2) In the two well separated beaks, the mandible of the right one lacks a symphysis and its two rami cross near their tips. 3) There is a single brain-case with one brain. No skull cap was formed and therefore only a small and malformed brain mass is protruding on the surface of the head (encephalocoele). The brain-weight is 30 g, which is very light if compared with that of a normal foetus brain at the same stage about

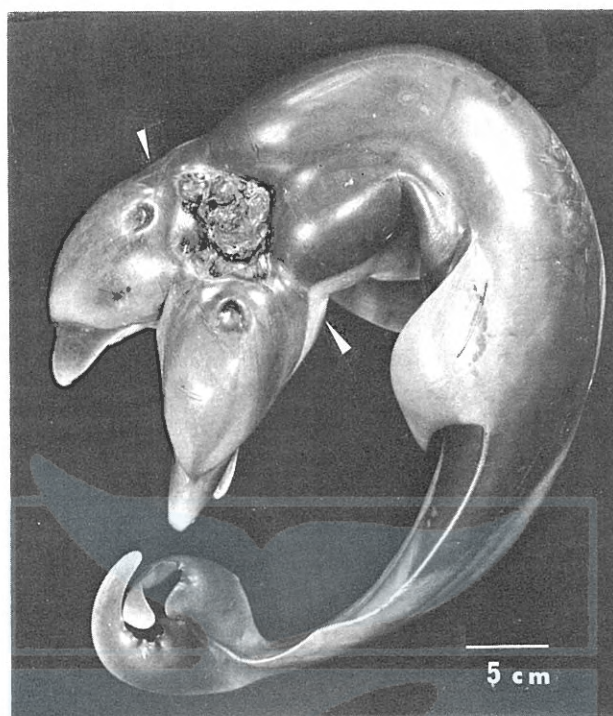


Fig. 1. Dorsal view of the striped dolphin dicephalic foetus. Note the two well-separated beaks and the encephalocoele immediately behind the blow-hole. White arrows show the positions of the eyes on the lateral facies.

250 g. On the abnormal hemispherical surface of the brain, one can see some gyri (Fig. 1). 4) An eye can be seen on the lateral side of each head just behind the oral angle. After dissection along the medial line of fusion, we found two other eye-balls embedded on each head. All those eye-balls show an almost normal size. The specimen thus has four eyes. 5) Fig. 2 shows a dorsal X-ray photograph in which one can see a petrous bone in normal position on each side, paired nasal bones, maxillar bones, one foramen magnum, etc. but no skull-cap as already mentioned. Tooth formation in the upper and lower jaws was progressing well. 6) Other parts of the external structures show no conspicuous differences from a normal foetus in either shape or size. For example, there are a pair of flippers, a tail and an umbilical cord on the abdomen, etc. 7) The visceral organs in the thoraco-abdominal cavities show an almost normal organ formation in comparison with the same stage of a normal foetus, except for some irregular shapes caused by the pressure of the curved vertebral column. In each oral cavity, one finds an abnormal small tongue-like muscular mass.

This teratological specimen can thus be characterized as a dicephaly, diprosopy and tetraophthalmy case in the dolphin. The specimen has not yet been finely dissected. The anatomical details of its internal organs, currently under investigation, will be reported elsewhere in a journal for morphological research.

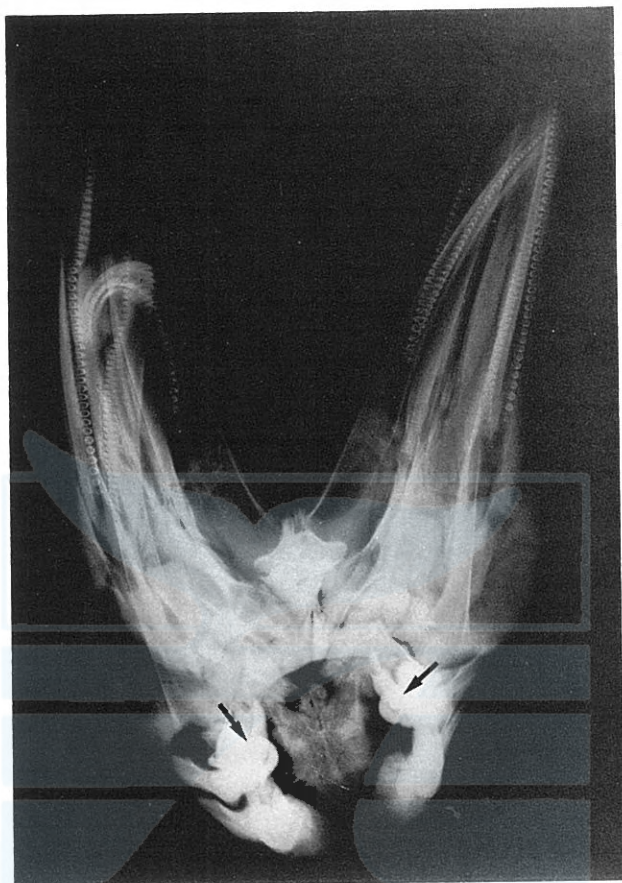

Fig. 2. An X-ray photograph taken in dorso-ventral direction. Arrows show the petrous bones. It can be noted that the skull-cap is unformed.

We wish sincere thanks to Prof. P. Pirlot, Université de Montréal, for critical reading of the manuscript.

#### REFERENCES

- KAMIYA, T. and N. MIYAZAKI. 1974. A malformed embryo of *Stenella coeruleoalba*. *Sci. Rep. Whales Res. Inst.*, 26: 259-263.
- KAWAMURA, A. 1969. Siamese twins in the sei whale *Balaenoptera borealis* Lesson. *Nature*, 221: 490-491.
- KAWAMURA, A. and K. KASHITA. 1971. A rare double monster of dolphin, *Stenella coeruleoalba*. *Sci. Rep. Whales Res. Inst.*, 23: 139-140.
- ZEMSKY, V. A. and G. A. BUDYLENKO. 1970. Siamese twins of humpback whale. *Atlant NIRO*, 24: 225-230.